



MRN:
Date 10/11/2016

Abdominal Ultrasound

Patient: **GE-DEMO GI** DOB: 03/12/1964
94203 Sacramento, 4416 Sycamore Ave
Exam date: 11/10/2016

Indication Follow-up. Jaundice.

Liver Cirrhosis: rounded caudal liver margin, nonductile, rarefacted and narrowed intrahepatic portal, and liver veins.
Length 17.0 cm. Width 13.0 cm. Max. diameter of CBD 5 mm.

Gallbladder Polyp: Small polyp.
Length 4.0 cm. Width 3.0 cm. Height 2.0 cm. Volume 12.6 cm³. Wall thickness 2.9 mm.

Bile Ducts normal
Max. diameter of CBD 5 mm.

Spleen normal size, homogeneous, no focal lesions, clear hilum
Length 6.6 cm. Width 6.1 cm.

Right Kidney normal
Length 9.6 cm. Width 4.3 cm. Height 5.2 cm. Volume 112.4 cm³.

Left Kidney normal
Length 11.0 cm. Width 4.9 cm. Height 6.1 cm. Volume 172.2 cm³.

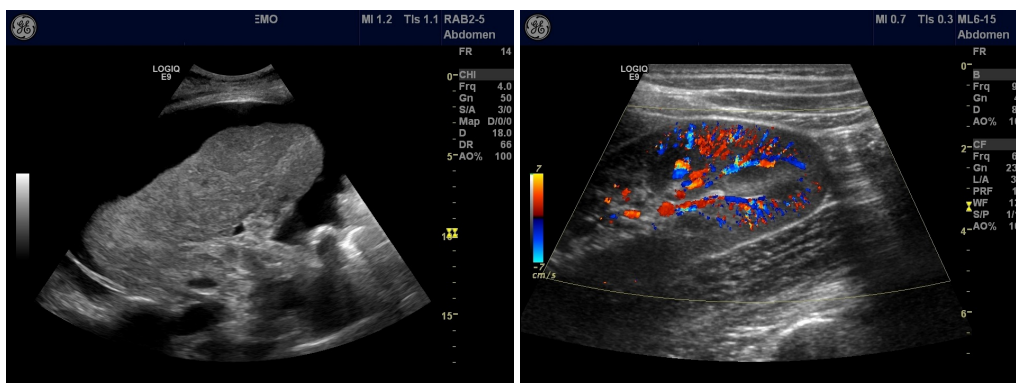
Bladder normal

Abdominal Aorta normal.

Inferior Vena Cava normal.

Peritoneum / Ascites Ascites.

Follow-up A repeat evaluation is recommended in one month.



John Mills
Sonographer

Dr. Stephanie Silver
Performing physician