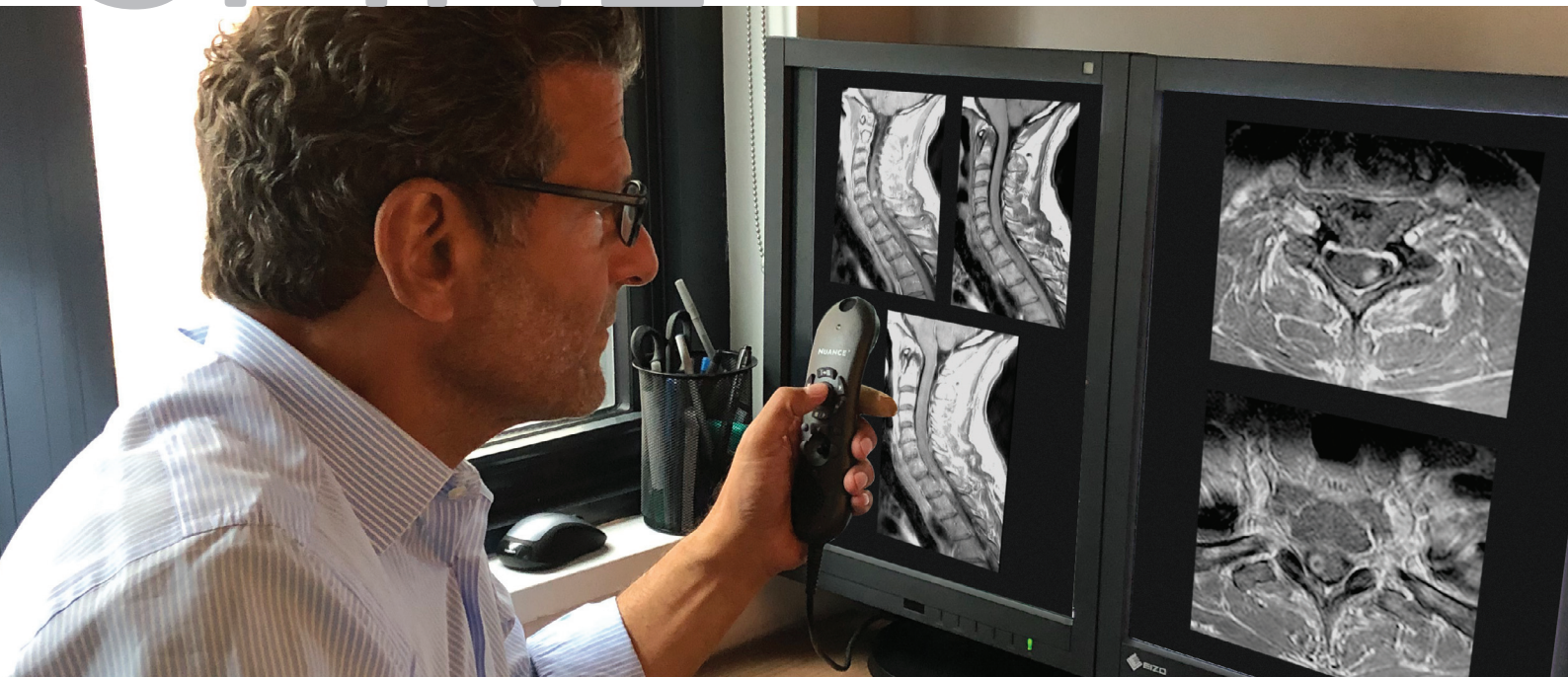




SPINE



Case studies from Lawrence N Tanenbaum, MD FACR using macrocyclic CLARISCAN™ (gadoteric acid)

Lawrence N Tanenbaum, MD FACR is Vice President/Chief Technology Officer Director of CT, MR and Advanced Imaging for RadNet, a large network of outpatient diagnostic imaging centres in USA. Dr Tanenbaum has 37+ years experience in the medical field, is a member of editorial boards of several journals/educational organizations and a reviewer for scientific journals. He has authored 100+ scholarly and peer-reviewed articles, chairs educational/academic meetings, and has delivered 2000+ invited global lectures.

All case study images courtesy of Lawrence N Tanenbaum, MD FACR and RadNet.

macrocyclic
Clariscan™
gadoteric acid

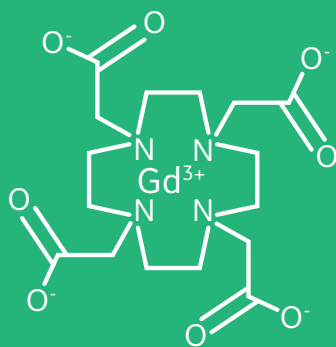
Clariscan™

Macrocyclic, ionic GBCA

Cage-like structure encloses and tightly binds the Gd^{3+} ion¹

Highly stable²

Rapid biodistribution and elimination³

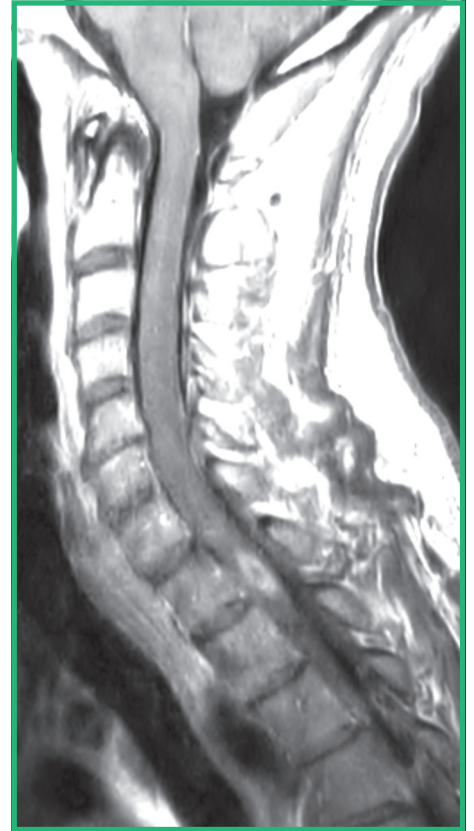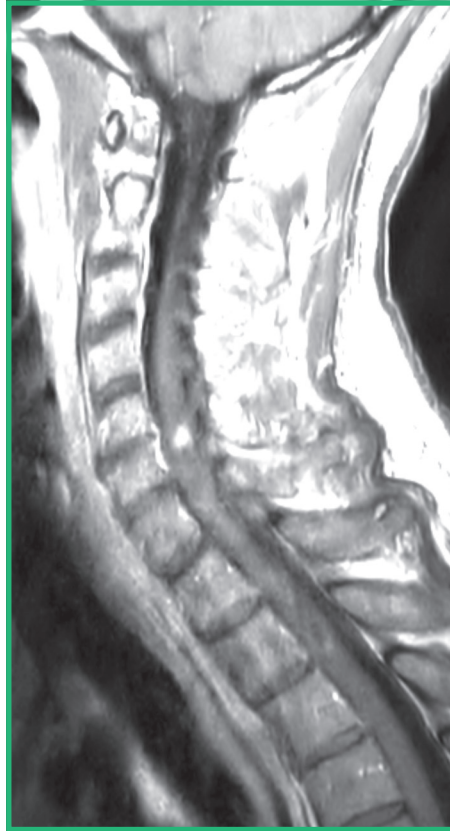
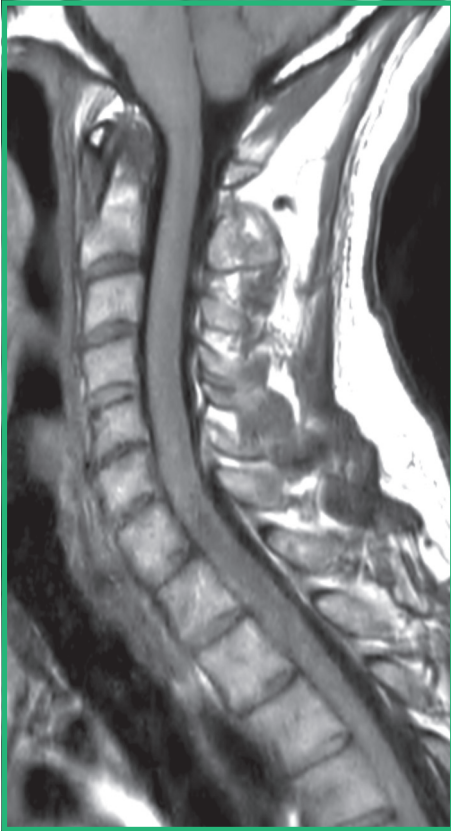


Case study 1 (cont'd)

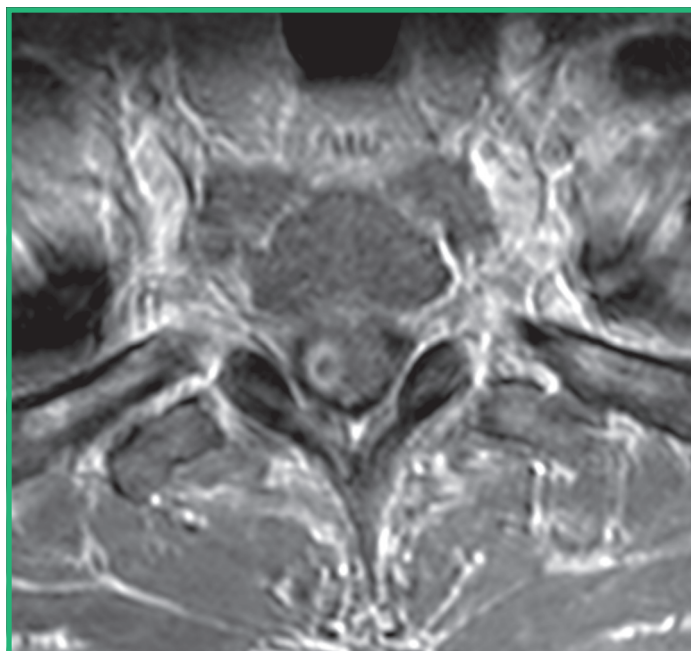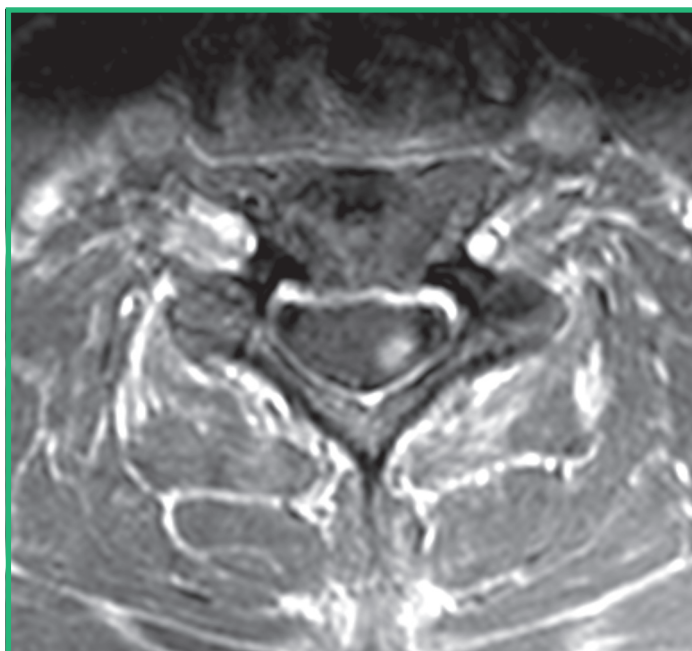
macrocyclic
Clariscan™
gadoteric acid

Pre-contrast T1WI

Post-contrast T1WI



Post-contrast T1



- Nodular and ring enhancing lesions within the cord consistent with myelitis

Imaging findings

Nodular and ring enhancing lesions within the cord consistent with myelitis.
No evidence of abnormality on brain or optic nerve imaging

Diagnosis

MRI results are consistent with myelitis

Treatment

Medical therapy

Case study 2

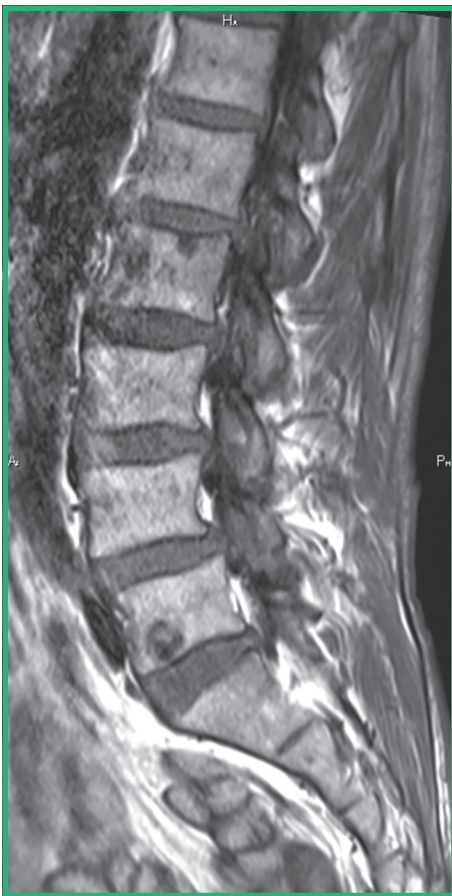Clinical presentation

72-year-old male weighing 64 kg, presented with back pain; history of prostate CA

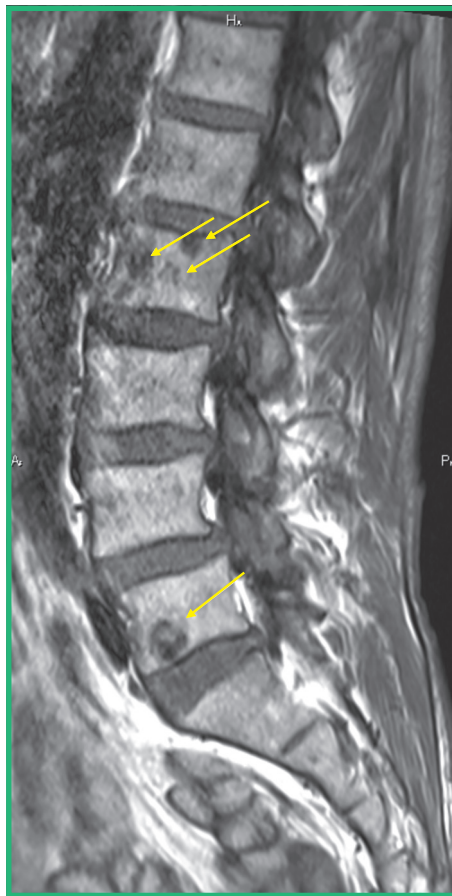Imaging

MRI of the spine without contrast and with 14 mL of Clariscan

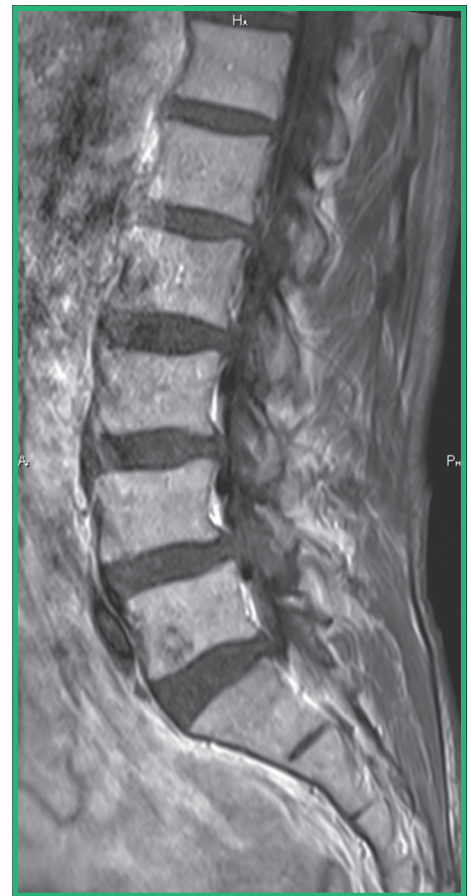Pre-contrast T1



Pre-contrast T1



Post-contrast T1

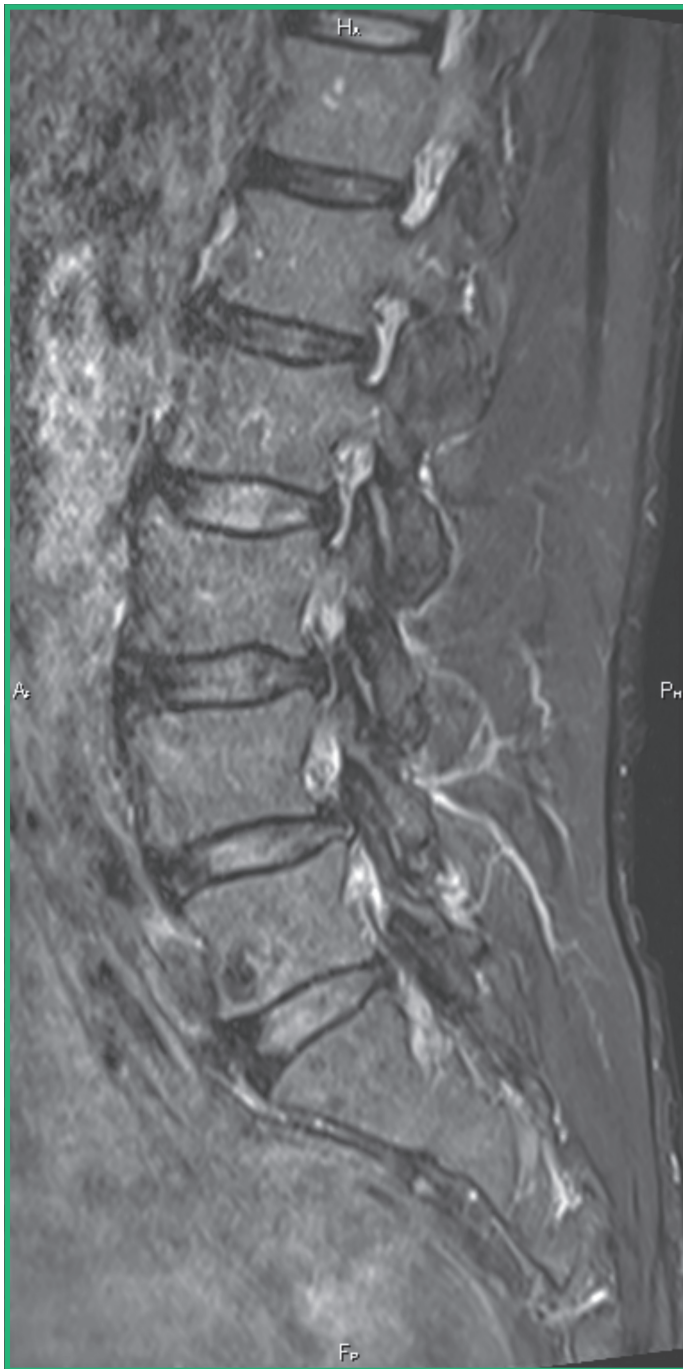


- Lesions at L2 and L5 which fill in/enhance post-contrast (arrows)

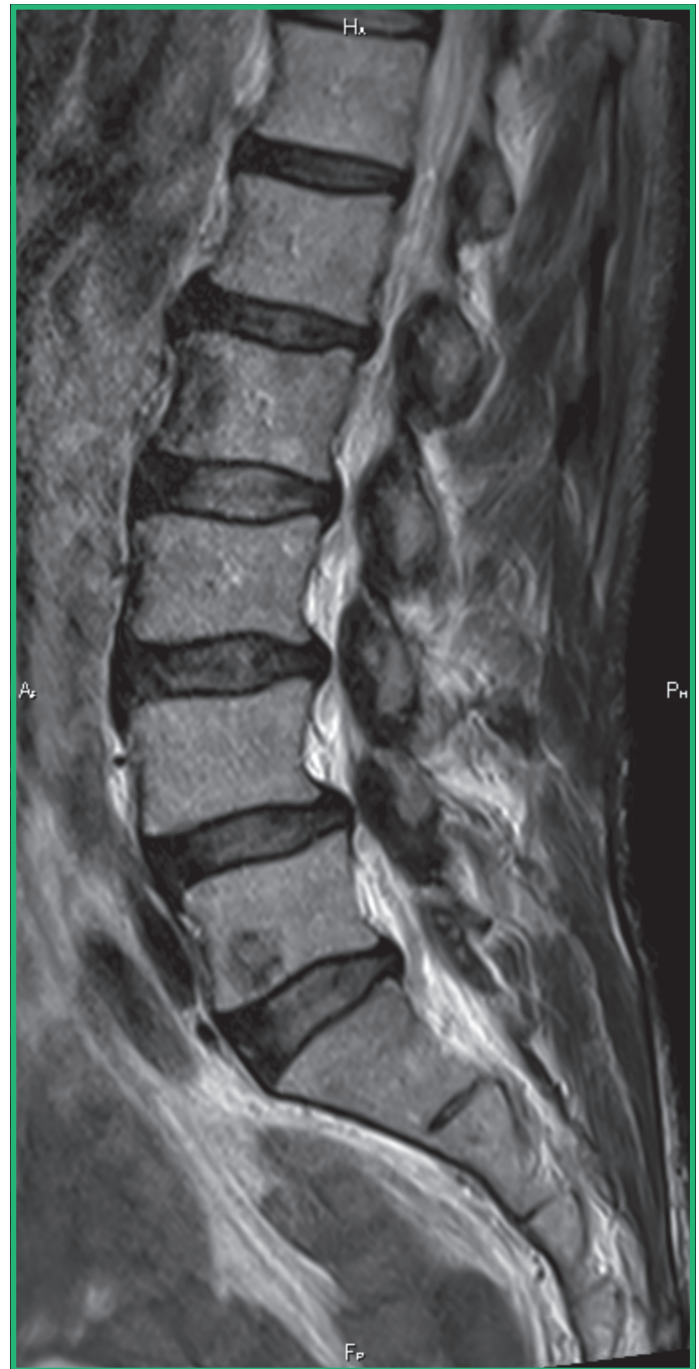Case study 2 (cont'd)

macrocyclic
Clariscan™
gadoteric acid

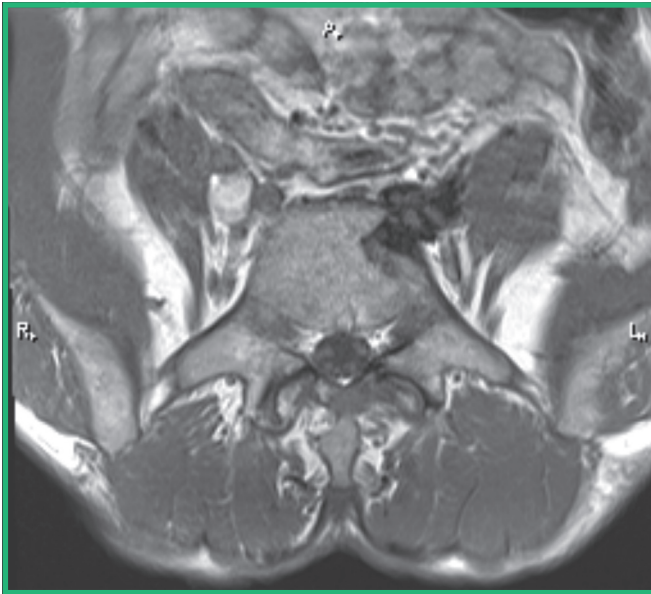
STIR



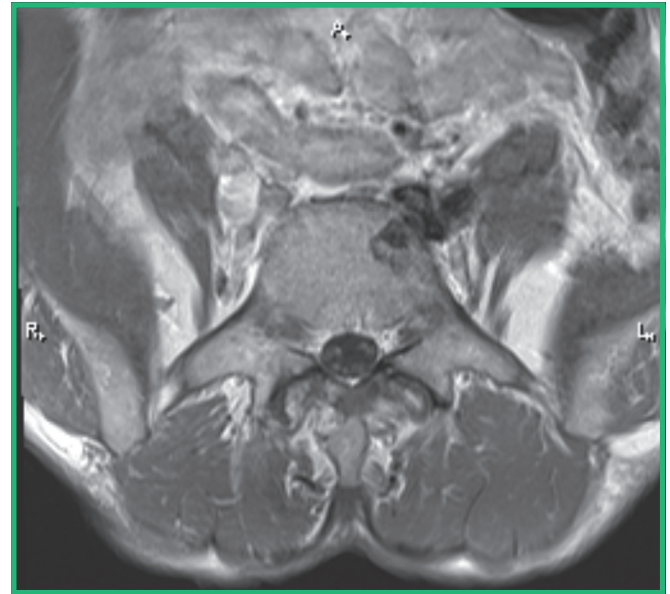
T2



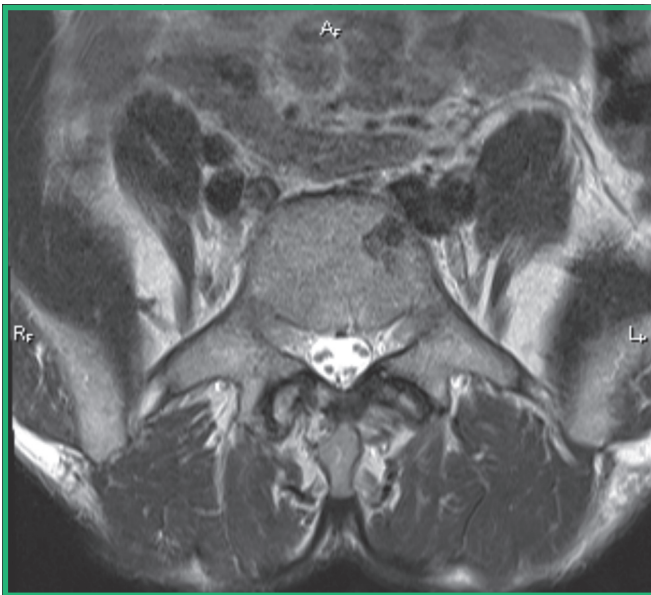Pre-contrast T1



Post-contrast T1



T2



- Partially enhancing lesion within the anterior aspect of the S1 vertebral body

Imaging findings

Lesions at L2 and L5 which fill in/enhance post-contrast

Diagnosis

MRI results are consistent with metastatic disease

Treatment plan

Radiation and chemotherapy

Case study 3

macrocyclic
Clariscan™
gadoteric acid

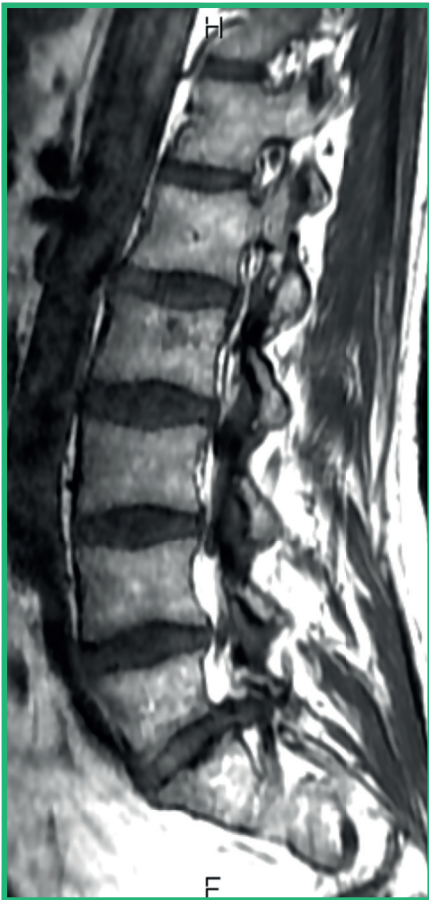Clinical presentation

45-year-old male weighing 86 kg, presented with back pain and left side S1 radiculopathy; prior surgery at L5-S1

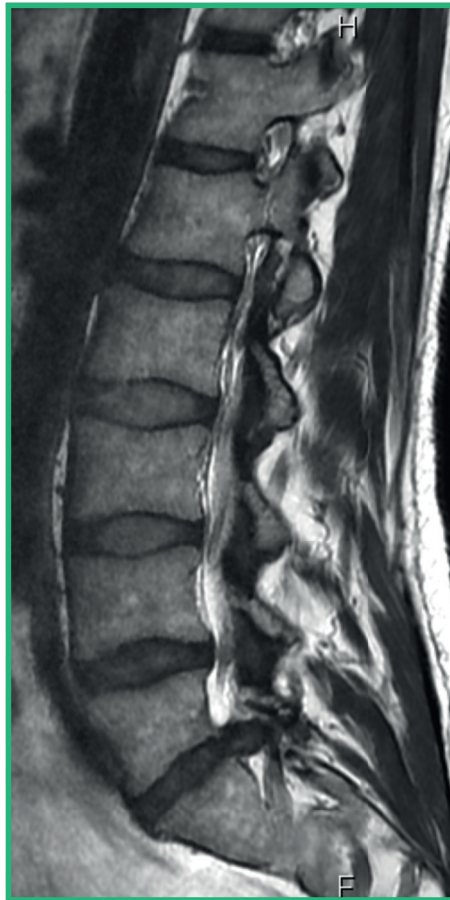
Imaging

MRI of the spine without contrast and with 19 mL of Clariscan

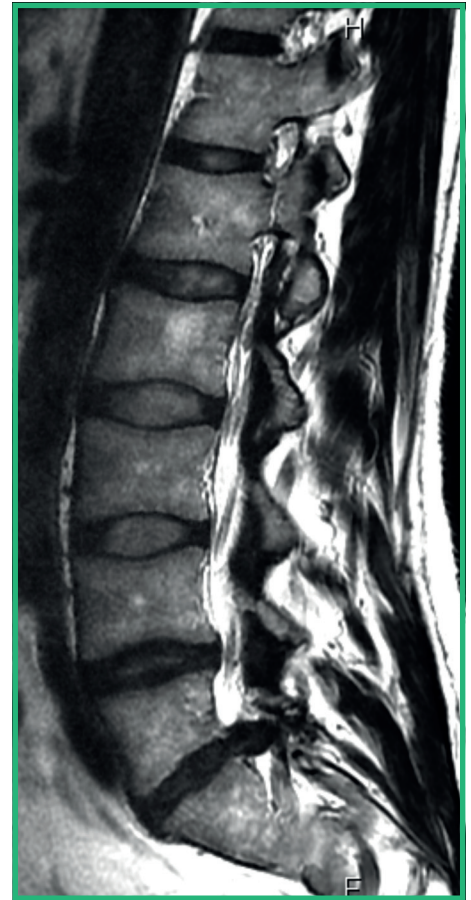
Pre-contrast T1



PD



T2

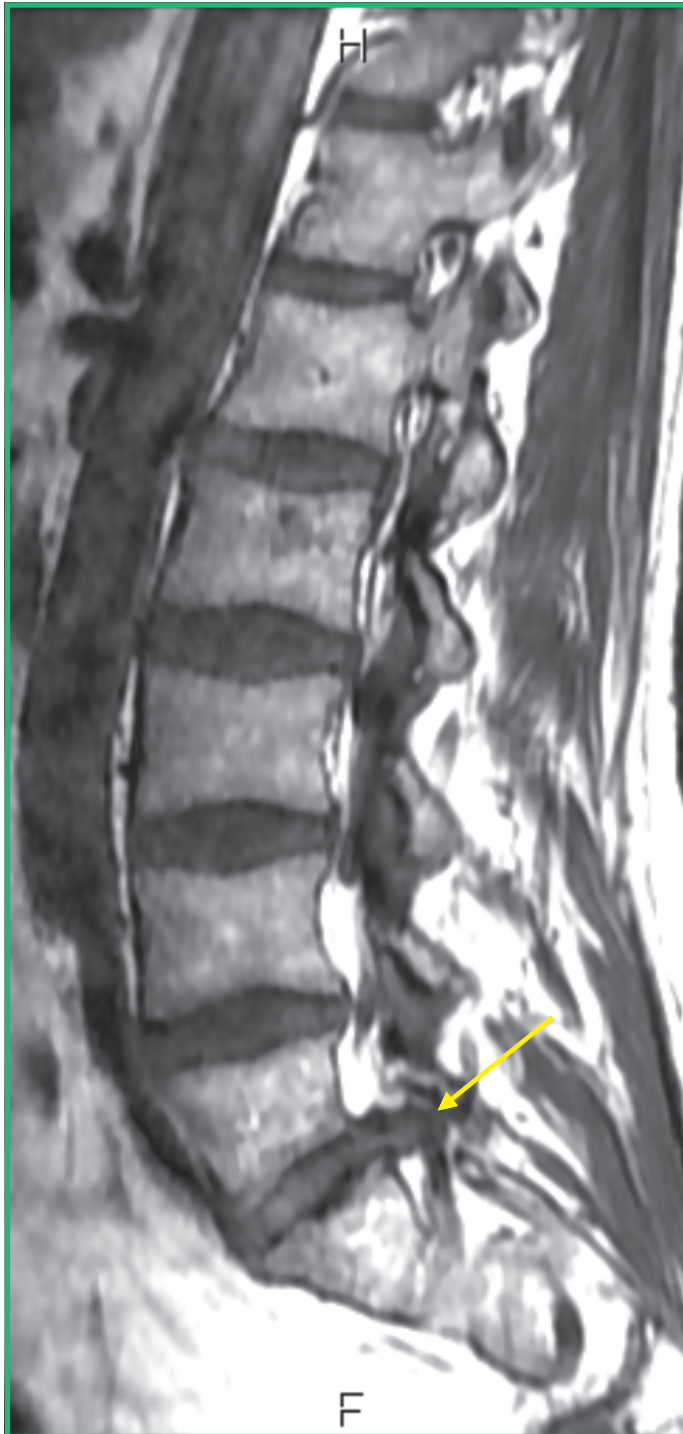

- Scans reveal abnormal anterior extradural soft tissue to the left of midline at L5-S1

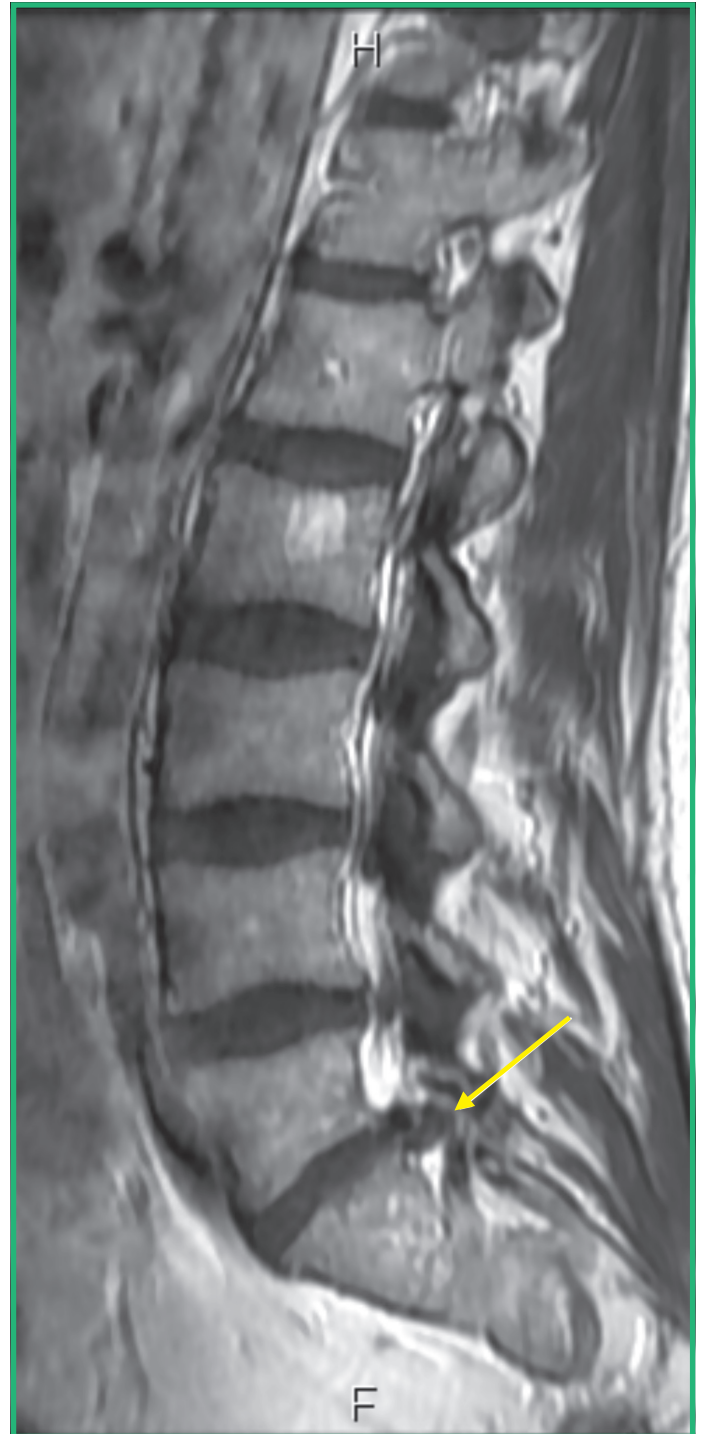
Case study 3 (cont'd)

macrocyclic
Clariscan™
gadoteric acid

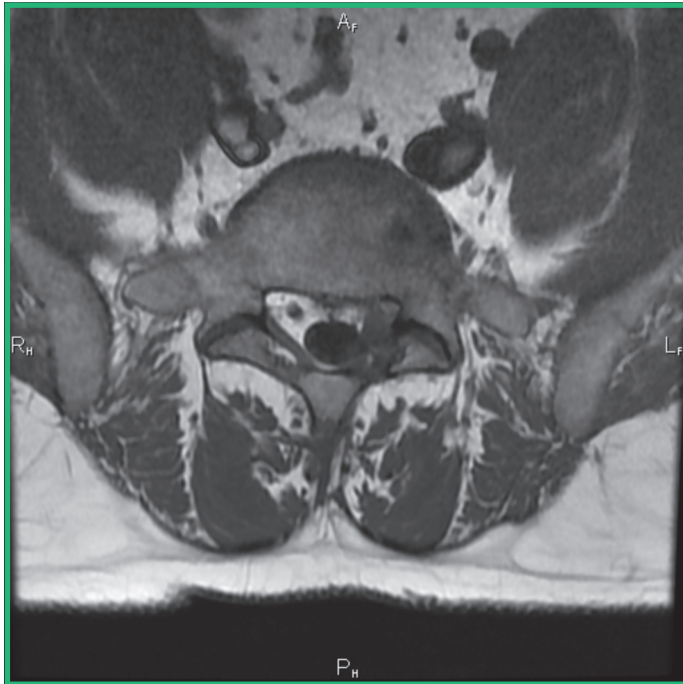
Pre-contrast T1



Post-contrast T1

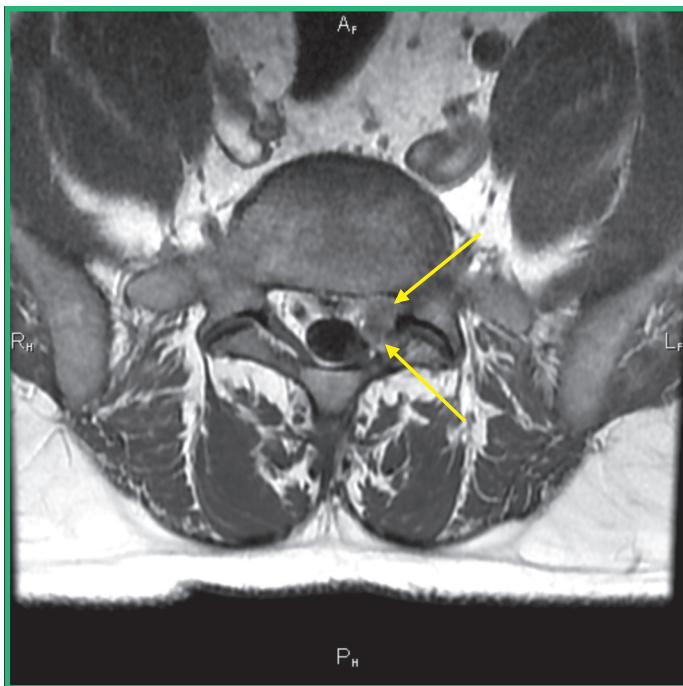


- Images demonstrate anterior extradural nonenhancing tissue at L5-S1 consistent with a recurrent herniation



Pre-contrast T1

- Abnormal soft tissue obscuring the tissue planes with the left S1 nerve root



Pre-contrast T1

- Island of nonenhancing tissue within a 'sea' of enhancement at L5-S1 consistent with a recurrent herniation which displaces the left S1 root posteriorly
- Herniated material (upper/anterior arrow)
- Displaced S1 root (lower/posterior arrow)

Imaging findings

Island of nonenhancing tissue within a 'sea' of enhancement at L5-S1 consistent with a recurrent herniation

Diagnosis

MRI results are consistent with recurrent herniation

Treatment plan

Repeat surgery

Case study 4

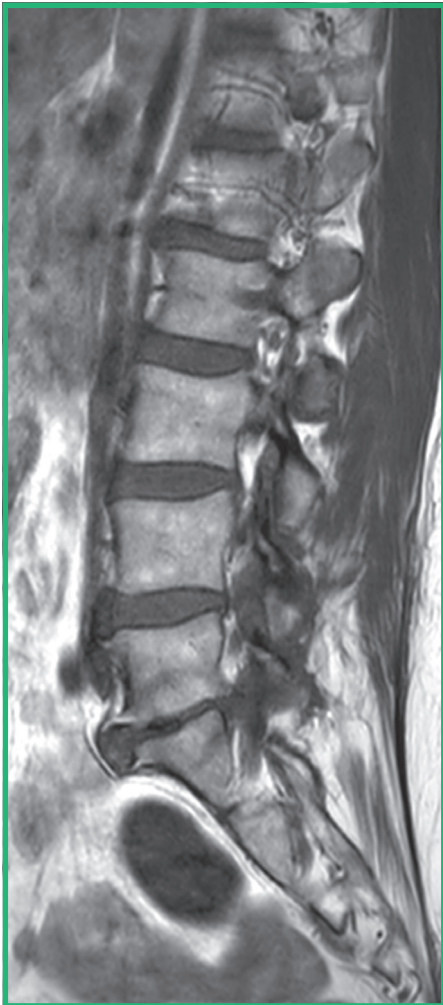Clinical presentation

60-year-old female weighing 64 kg, presented with right sided back pain and right sided radiculopathy; prior surgery at L5-S1 for herniation

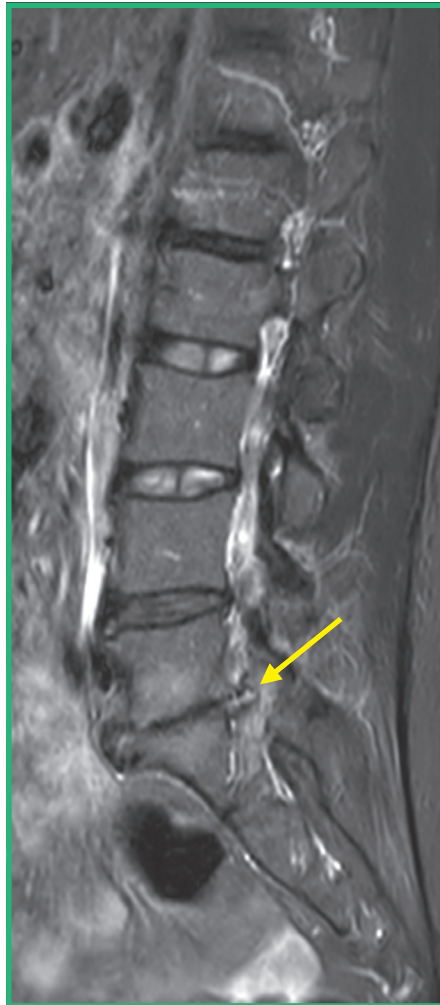Imaging

MRI of the spine without contrast and with 14 mL of Clariscan

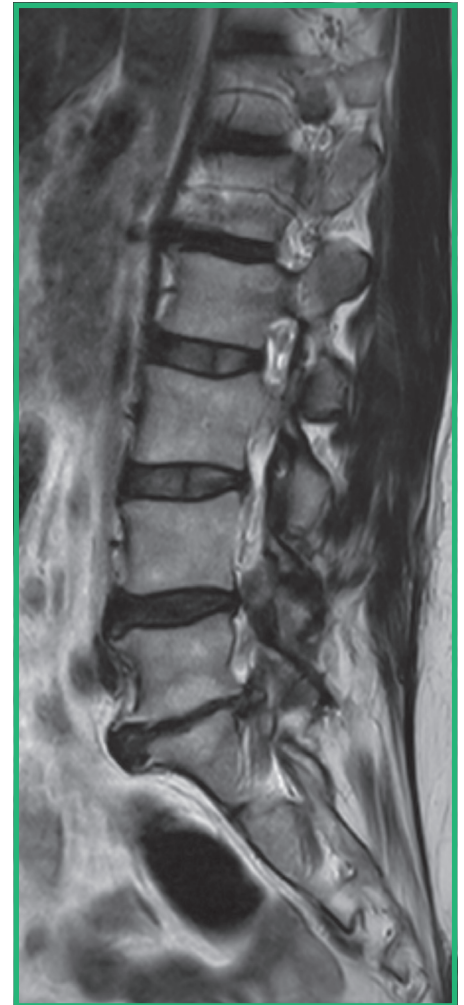Pre-contrast T1



STIR

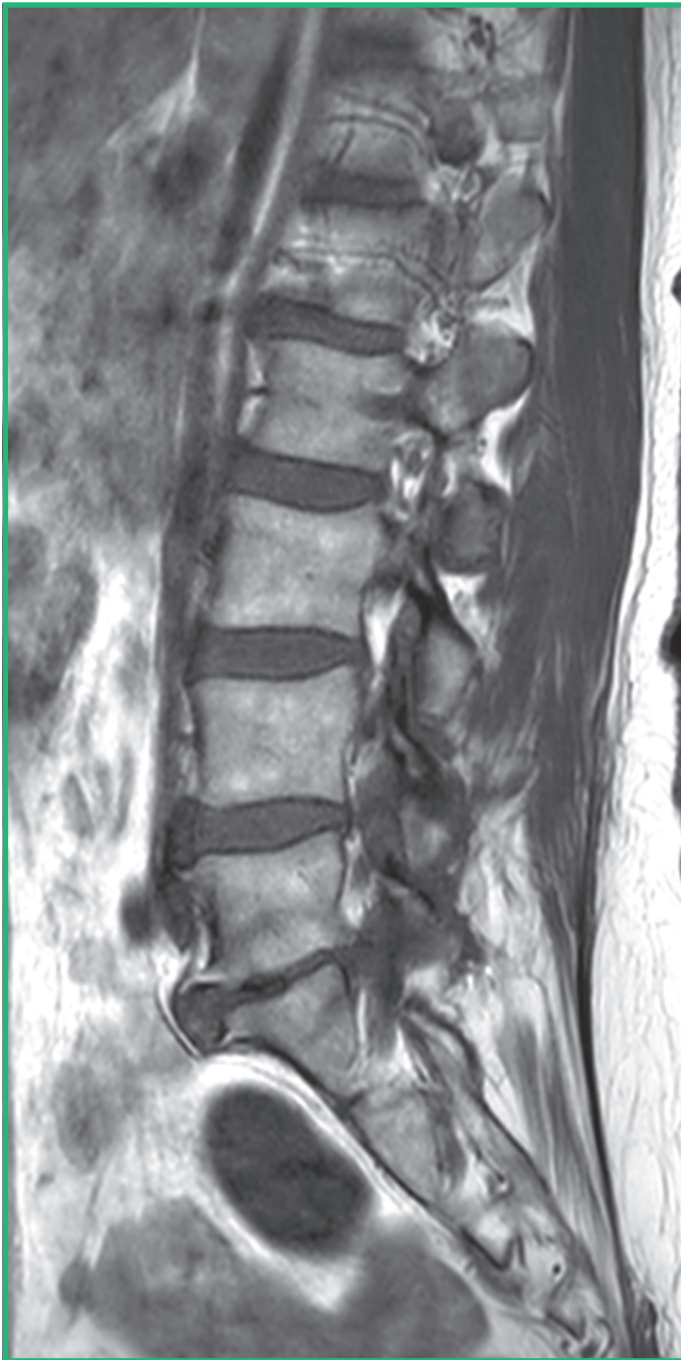

T2

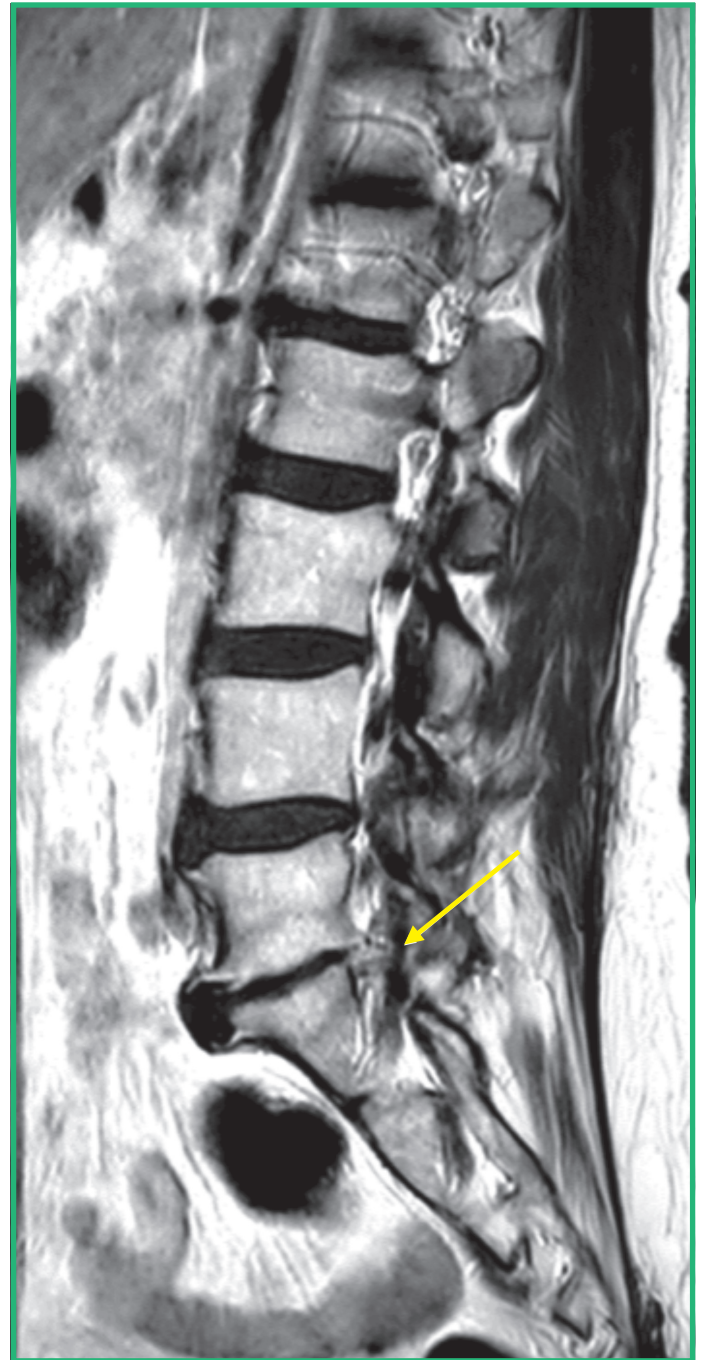


- Abnormal anterior extradural tissue at the L5-S1 level which could reflect postsurgical change or recurrent herniation

Pre-contrast T1

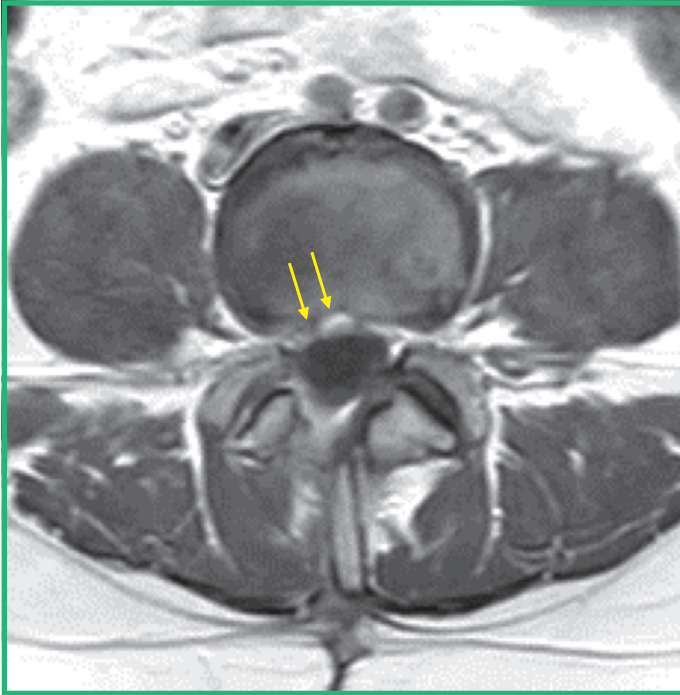


Post-contrast T1

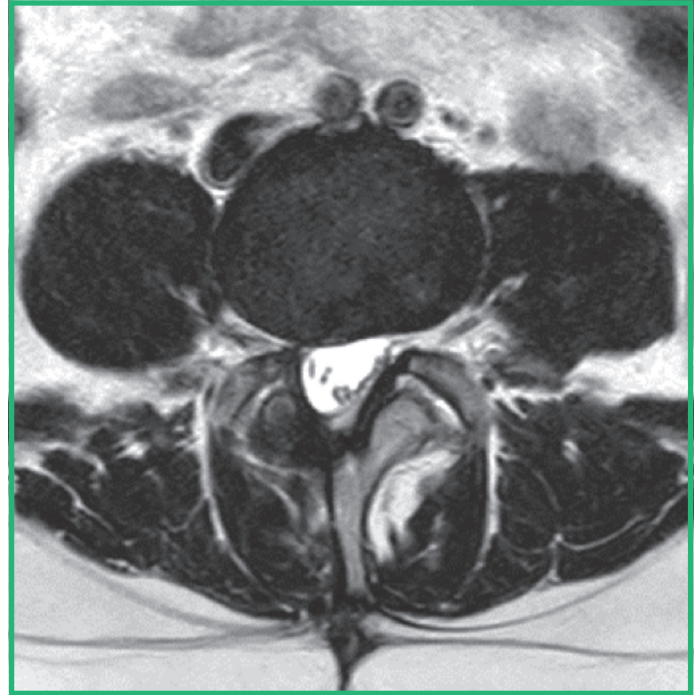


- Enhancing anterior extradural tissue at the L5-S1 level consistent with postsurgical change

Post-contrast T1



Non-contrast T2



- Right sided hemilaminotomy and enhancing epidural soft tissue consistent with treatment-related change

Imaging findings

Right sided hemilaminotomy and enhancing epidural soft tissue consistent with treatment-related change

Diagnosis

MRI results are consistent with postsurgical change

Treatment plan

Conservative treatment

Case study 5

macrocyclic
Clariscan™
gadoteric acid

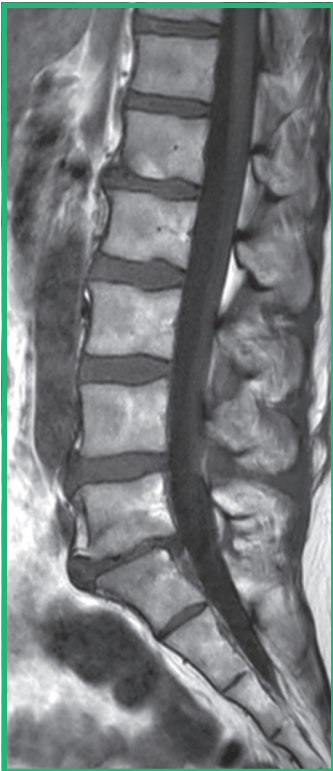
Clinical presentation

60-year-old female weighing 64 kg, presented with right sided back pain and right sided radiculopathy; prior surgery at L5-S1 for herniation

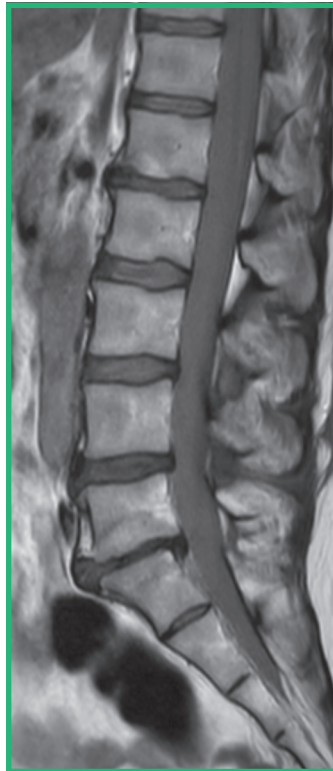
Imaging

MRI of the spine without contrast and with 14 mL of Clariscan

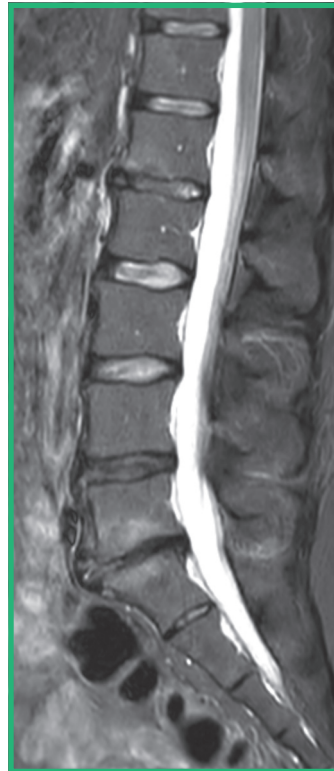
Pre-contrast T1



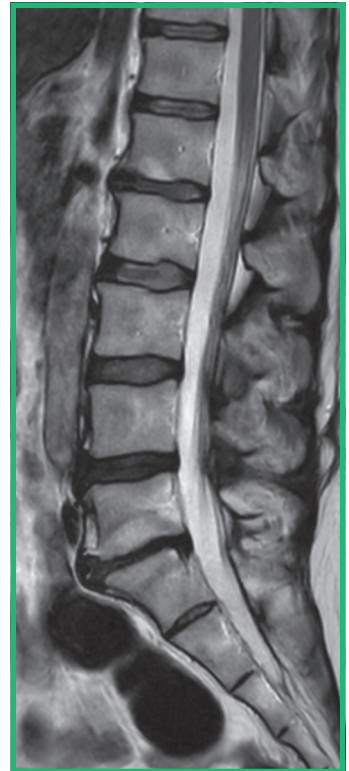
Proton density



STIR

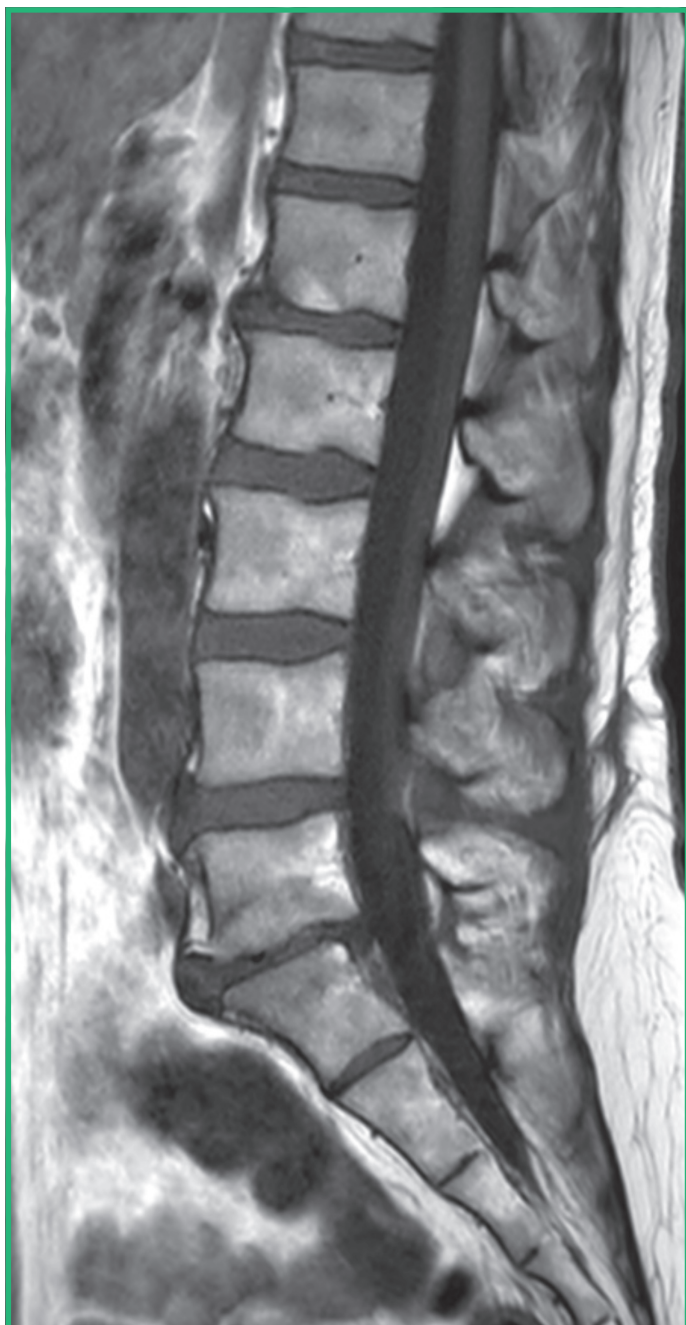


T2

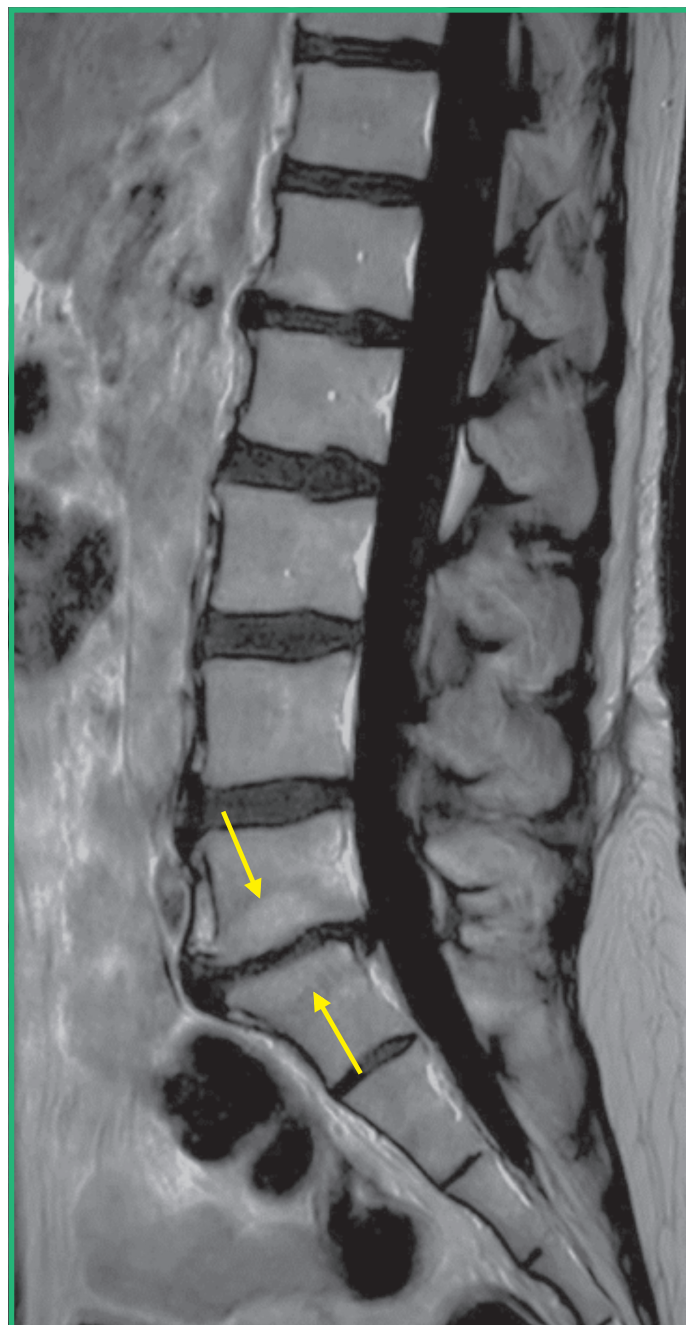


- Non-contrast images demonstrate loss of disc height with mixed endplate region signal changes and loss of disc height at L4-L5

Pre-contrast T1



Post-contrast T1



- Loss of disc height with mixed endplate region signal changes and enhancement

Imaging findings

Loss of disc height with mixed endplate region signal changes and enhancement which may be clinically symptomatic

Diagnosis

MRI results are consistent with symptomatic degenerative endplate changes

Treatment plan

Conservative treatment and physical therapy

Case study 6

macrocyclic
Clariscan[™]
gadoteric acid

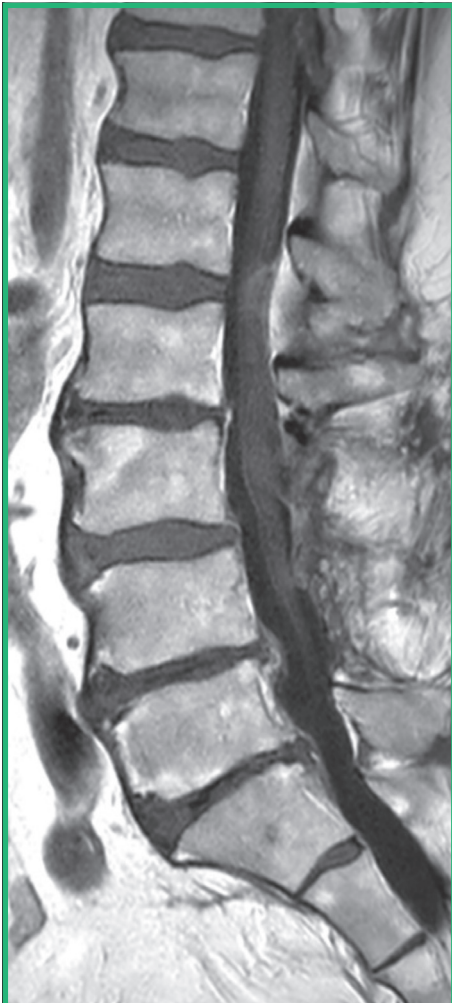Clinical presentation

62-year-old male weighing 91 kg, presented with back pain

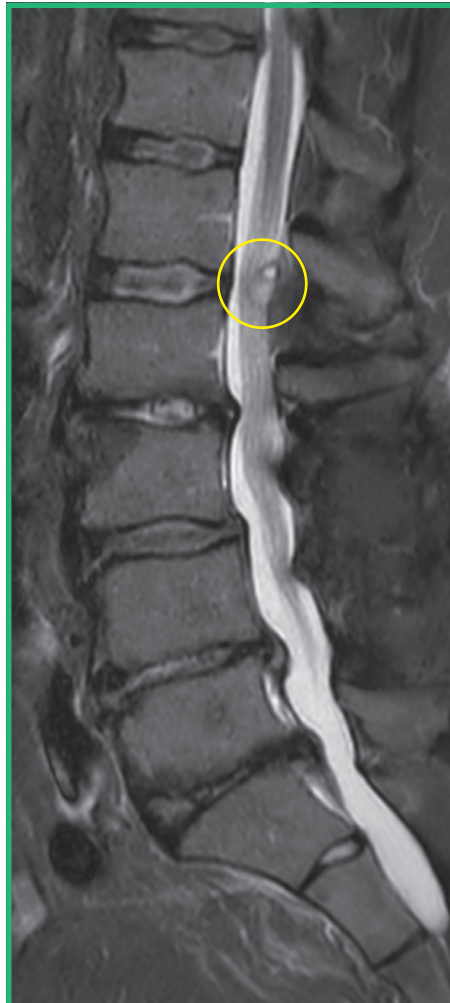Imaging

MRI of the spine without contrast and with 20 mL of Clariscan

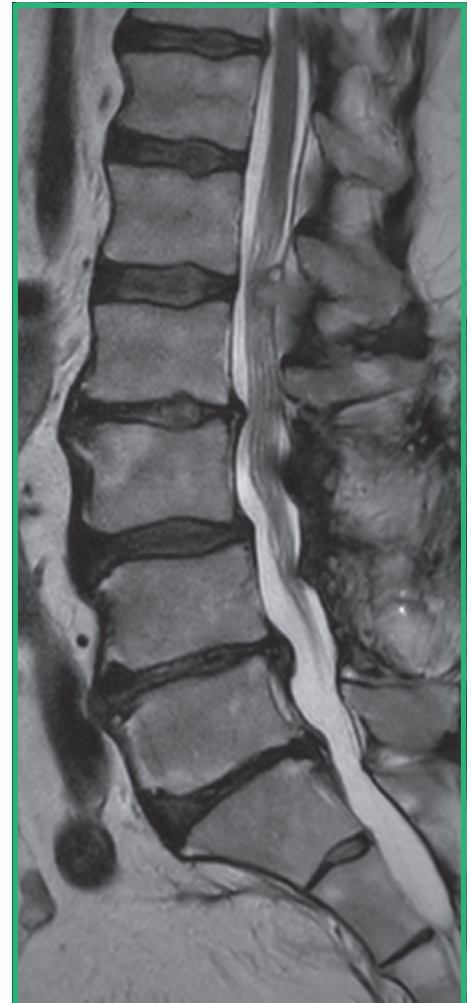Pre-contrast T1



STIR



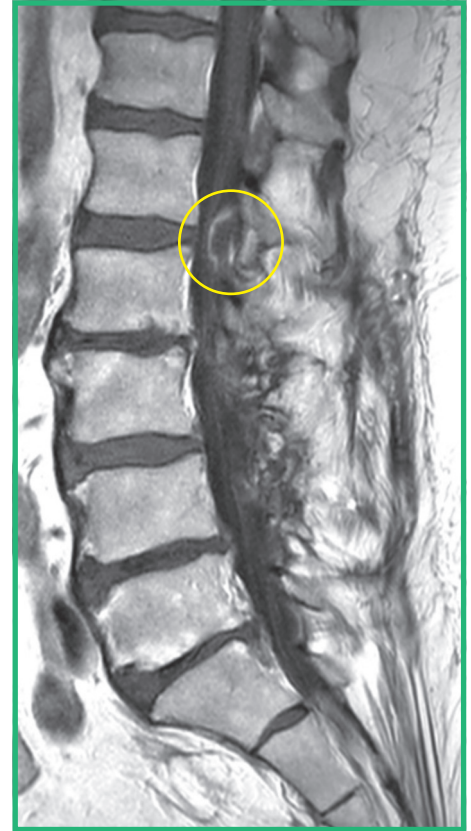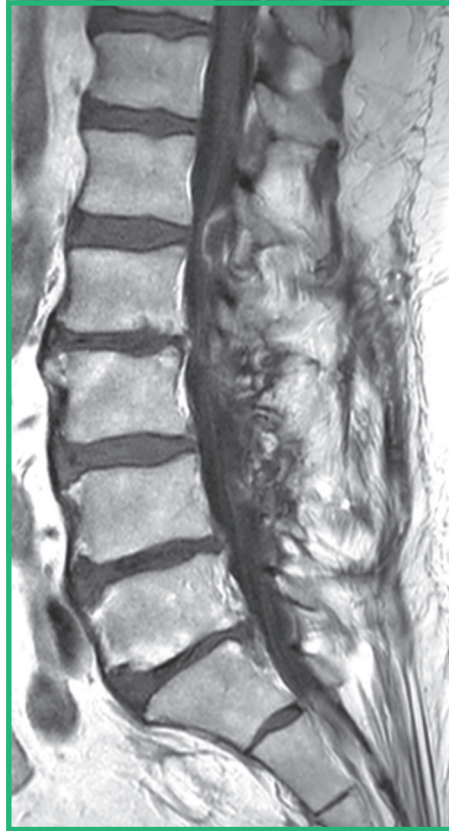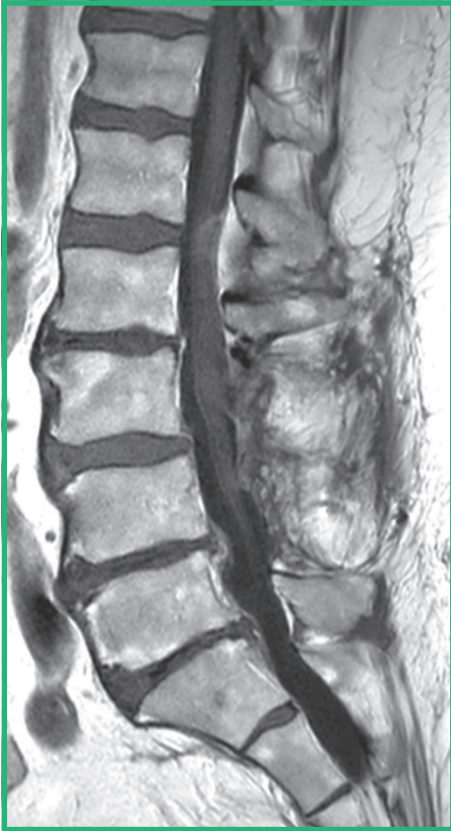T2



- Dorsal extradural lesion at L1-2 indenting the thecal sac (circle)

Pre-contrast T1

Post-contrast T1



- Peripherally enhancing dorsal extradural lesion at L1-2 indenting the thecal sac

Imaging findings

Peripherally enhancing dorsal extradural lesion at L1-2 indenting the thecal sac

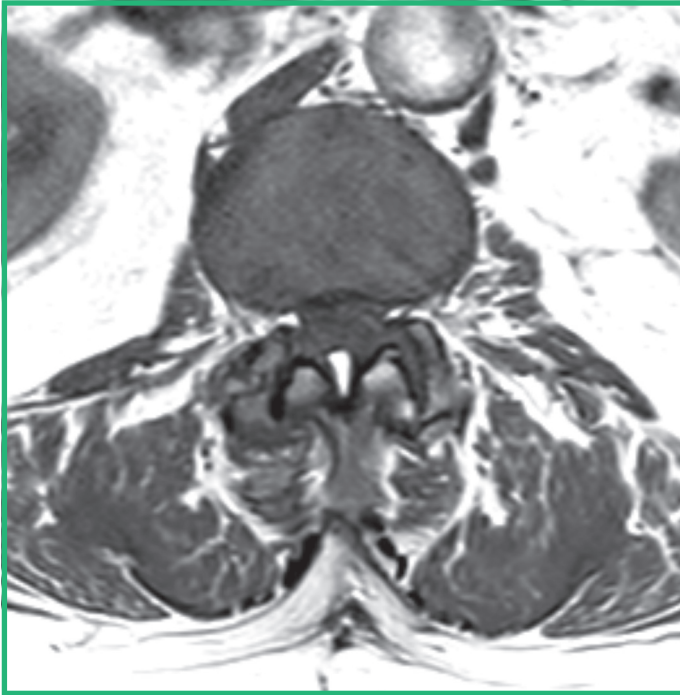
Diagnosis

MRI results are consistent with synovial cyst

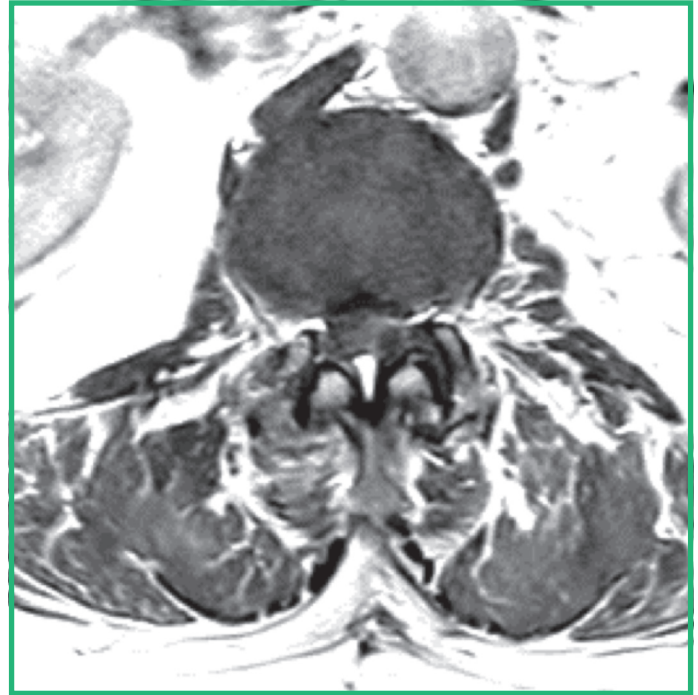
Treatment plan

Resection

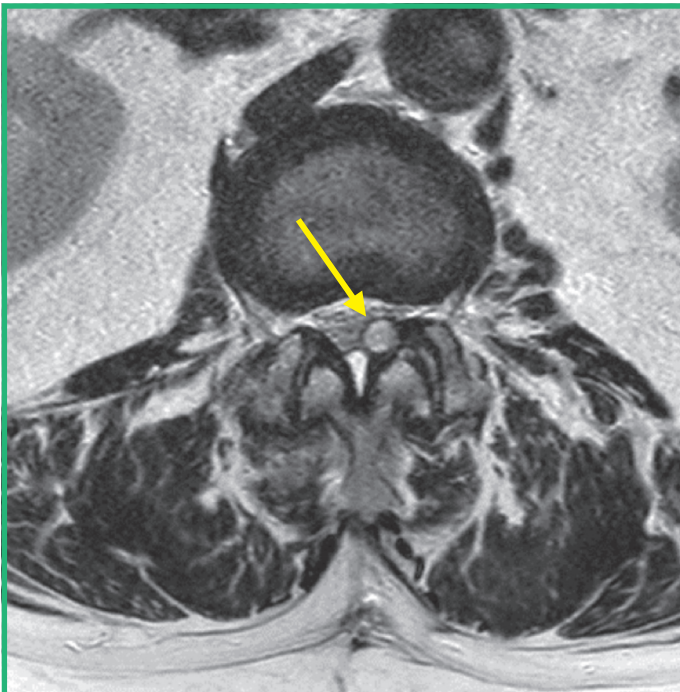
Pre-contrast T1



Post-contrast T1



Non-contrast T2



- Left sided dorsal extradural lesion at L1-2 indenting the thecal sac consistent with a facet joint synovial cyst



PRESCRIBING INFORMATION CLARISCAN™ – gadoteric acid

Please refer to full national Summary of Product Characteristics (SmPC) before prescribing. Further information available on request.

PRESENTATION Clariscan 0.5 mmol/mL solution for injection. Solution for injection containing 279.3 mg/mL gadoteric acid (as gadoterate meglumine) equivalent to 0.5 mmol/mL.

INDICATIONS For diagnostic use only. Clariscan should be used only when diagnostic information is essential and not available with unenhanced magnetic resonance imaging (MRI). Contrast agent for contrast enhancement in MRI for a better visualisation/delineation. Adult and paediatric population (0-18 years): lesions of the brain, spine, and surrounding tissues. Adults and children over 6 months Whole body MRI. Non-coronary angiography in adults only.

DOSAGE AND METHOD OF ADMINISTRATION This medicinal product should only be administered by trained healthcare professionals with technical expertise in performing and interpreting gadolinium enhanced MRI. The lowest dose that provides sufficient enhancement for diagnostic purposes should be used. The dose should be calculated based on the patient's body weight, and should not exceed the recommended dose per kilogram of body weight detailed in this section.

MRI of brain and spine: Adults: The recommended dose is 0.1 mmol/kg BW, i.e. 0.2 mL/kg BW. In patients with brain tumours, an additional dose of 0.2 mmol/kg BW, i.e. 0.4 mL/kg BW, may improve tumor characterisation and facilitate therapeutic decision making. **Children (0-18 years):**

The recommended and maximum dose of Clariscan is 0.1 mmol/kg body weight. Do not use more than one dose during a scan. Careful consideration in neonates up to 4 weeks and infants up to 1 year of age. Lack of information on repeated administration, Clariscan injections should not be repeated before 7 days. **Whole body MRI (including lesions of the liver, kidneys, pancreas, pelvis, lungs, heart, breast, and musculoskeletal system): Adults and children over 6 months:**

The recommended dose is 0.1 mmol/kg BW, i.e. 0.2 mL/kg BW. **Angiography: Adults only:** The recommended dose, IV injection is 0.1 mmol/kg BW, i.e. 0.2 mL/kg BW. **Impaired renal function:**

Clariscan should only be used in patients with severe renal impairment (GFR < 30 mL/min/1.73 m²) and in patients in the perioperative liver transplantation period after careful risk/benefit assessment and if the diagnostic information is essential and not available with non-contrast enhanced MRI. If it is necessary to use Clariscan the dose should not exceed 0.1 mmol/kg body weight.

Clariscan injections should not be repeated before 7 days. **Impaired hepatic function:** The adult dose applies. Caution recommended, especially in perioperative liver transplantation period.

Elderly (aged 65 years and above): No dosage adjustment, but exercise caution.

CONTRAINDICATIONS Hypersensitivity to gadoteric acid, to meglumine or to any medicinal products containing gadolinium.

WARNINGS AND PRECAUTIONS Appropriate facilities should be readily available for any complication, as well as for emergency treatment of severe reaction to the contrast agent (e.g. hypersensitivity, seizures). The usual precaution for MRI examination should be taken. Regarding any metallic object such as exclusion of patients with pacemakers, vascular clips, infusion pumps, nerve stimulators, cochlear implants, or suspected intracorporeal metallic foreign bodies, particularly in the eye.

Not for intrathecal use: For intravenous injection only. Clariscan must not be administered by subarachnoid (or epidural) injections. **Extravasation:** In the event of extravasation local intolerance reactions may be observed, necessitating short term local treatment. **Hypersensitivity reactions:** Hypersensitivity reactions can occur, including life-threatening, and may be either allergic or non-allergic. They can be either immediate (less than 60 minutes), or delayed (up to 7 days).

Anaphylactic reactions can occur immediately and can be fatal. Symptoms of an existing asthma may be aggravated. Hypersensitivity reactions can be aggravated in patients on beta-blockers, particularly those with bronchial asthma. These patients may be refractory to standard treatment of hypersensitivity reactions with beta-agonists. Caution in patients with a history of allergy (e.g. fish and seafood allergy, hay fever, hives), sensitivity to contrast media and bronchial asthma and premedication with antihistamines and/or glucocorticoids may be considered. Appropriate support measures should be available. **Nephrogenic Systemic Fibrosis (NSF):** Reports of NSF associated with use of some gadolinium-containing contrast agents in patients with acute or chronic severe renal impairment (GFR < 30 mL/min/1.73 m²). Incidence of acute renal failure is high in patients undergoing liver transplantation. Clariscan should only be used in patients with severe renal impairment and in patients in the perioperative liver transplantation period after careful risk/benefit assessment and if the diagnostic information is essential and not available with non-contrast enhanced MRI. Prior to administration of Clariscan, it is recommended that all patients are screened for renal dysfunction. **CNS disorders:** Special precaution is necessary in patients with a low threshold for seizures. **Cardiovascular disease:** Clariscan should only be administered after careful benefit assessment. **Patient preparation:** Nausea and vomiting are known possible undesirable effects when using MRI contrast agents. The patient should therefore refrain from eating for 2 hours prior to the investigation.

UNDESIRABLE EFFECTS NSF [see Warnings and Precautions]. **Clinical Studies Experience:** **Immune system disorders:** Uncommon: Hypersensitivity, anaphylactic reaction, anaphylactoid reaction. **Psychiatric disorders:** Very rare: Agitation, anxiety. **Eye disorders:** Rare: Conjunctivitis, ocular hyperaemia, vision blurred, lacrimation increased, eyelid oedema. **Nervous system disorders:** Very common: Paraesthesia, headache. Rare: Dysgeusia. Very rare: Coma, convulsion, syncope, presyncope, dizziness, parosmia, tremor. **Cardiac disorders:** Very rare: Cardiac arrest, bradycardia, tachycardia, arrhythmia, palpitations. **Respiratory, thoracic and mediastinal disorders:** Very rare: Respiratory arrest, Rare: Pulmonary oedema, bronchospasm, laryngospasm, pharyngeal oedema, dyspnoea, nasal congestion, sneezing, cough, dry throat. **Gastrointestinal disorders:** Common: Nausea, vomiting. Very rare: Diarrhoea, abdominal pain, salivary hypersecretion. **Skin and subcutaneous system disorders:** Common: Pruritus, erythema, rash. Rare: Urticaria, hyperhidrosis. Very rare: Eczema, angioedema. Isolated cases of NSF have been reported with gadoteric acid, most of which were in patients co-administered other gadolinium-containing contrast agents. **Vascular disorders:** Very rare: Hypotension, hypertension, vasodilatation, pallor. **Musculoskeletal and connective tissue disorders:** Very rare: Muscle contracture, muscular weakness, back pain. **General disorders and administration site conditions:** Common: Feeling hot, feeling cold, injection site. Very rare: Chest discomfort, fever, chills, face oedema, asthenia, injection site discomfort, back pain, malaise, thoracic pain, superficial phlebitis, decreased oxygen saturation. Injection site reaction, injection site oedema, injection site extravasation, injection site inflammation (in case of extravasation), injection site necrosis (in case of extravasation). See full SmPC for adverse reactions reported with other intravenous MRI contrast agents. **Postmarketing experience:** The most commonly reported adverse reactions following administration are nausea, vomiting, pruritus and hypersensitivity reactions. The most frequently observed hypersensitivity reactions are localised, extended or generalised skin reactions which most often occur immediately (during the injection or within one hour after the start of injection) or sometimes delayed (one hour to several days after injection). Immediate reactions include one or more effects, which appear simultaneously or sequentially, which are most often cutaneous, respiratory and/or cardiovascular reactions. Each sign may be a warning sign of a starting shock and go very rarely to death. **DRUG INTERACTIONS** No formal studies. No interactions with other medicinal products have been observed. Beta-blockers, vasoactive substances, angiotensin-converting enzyme inhibitors, angiotensin receptor antagonists: These medicinal products induce decreased efficacy of cardiovascular compensation mechanisms of blood pressure. Contrast media may increase the incidence of hypersensitivity reactions in patients taking beta-blockers. **PREGNANCY AND LACTATION** No data in pregnant women. Clariscan should not be used during pregnancy unless the clinical condition of the woman requires use of gadoteric acid. **Nursing Mothers:** At clinical doses, no effects on the infant are anticipated due to the small amount excreted in milk and poor absorption from the gut. Continuing or discontinuing breast feeding for a period of 24 hours after administration, should be at the discretion of the doctor and lactating mother. **Fertility:** no clinical data. **SPECIAL POPULATIONS: Neonates and infants:** Clariscan should only be used in neonates up to 4 weeks of age and infants up to 1 year age after careful consideration. **Elderly (aged 65 years and above):** Patients should be screened due to age related decline in renal function. **OVERDOSE** Clariscan can be removed by haemodialysis. However, there is no evidence that haemodialysis is suitable for prevention of NSF. **EFFECTS ON THE ABILITY TO DRIVE AND USE MACHINES** No studies. Ambulant patients while driving vehicles or operating machinery should take into account that nausea may incidentally occur. **INSTRUCTIONS FOR USE AND HANDLING** For single use. The solution for injection should be inspected visually prior to use. Only clear solutions free of visible particles should be used. In neonates and infants the required dose should be administered by hand. The peel-off tracking label on the syringes/vials/bottles should be stuck onto the patient record. The dose used should also be recorded. See SmPC for full instructions. **MARKETING AUTHORISATION HOLDER** GE Healthcare AS, P.O. Box 4220 Nydalen, NO-0401 OSLO, NORWAY. **MARKETING AUTHORISATION NUMBER** PL 00637/0065 and PL 00637/0066. **CLASSIFICATION FOR SUPPLY** Subject to medical prescription. **DATE OF REVISION OF THE TEXT** May 2018. **Cost 10x15mL: £666**

Adverse events should be reported.
Reporting forms and information can be found at <https://yellowcard.mhra.gov.uk/>.
Adverse events should also be reported to GE Healthcare at gpv.drugsafety@ge.com.

Dr Tanenbaum is a consultant of GE Healthcare

References:

1. Tweedle MF et al. App Radiol 2014; (suppl): 1-11.
2. Port M et al. Biometals 2008; 21: 469-90.
3. Clariscan Summary of Product Characteristics (UK), April 2022.

GE Healthcare Limited, Pollards Wood, Nightingales Lane,
Chalfont St Giles, Buckinghamshire, England HP8 4SP
www.gehealthcare.com