



SIGNA™ Architect with the AIR™ family of technologies

**Making MRI scans more comfortable for patients –
Juravinski Cancer Center, Ontario, Canada**

Catering to a population of 2.2 million, Juravinski Cancer Center (JCC) receives a high volume of pathologies mainly referred for diagnosis, follow-up, and management. Well-regarded as the regional referral centre for hepatobiliary and pancreatic surgery, gynecologic oncology, neuro-oncology, JCC is one of the busiest cancer centers in the country.



- JCC clinics receive and process referrals for more than 7,000 new patients per year
- Equipped with one 3.0T MRI – GE SIGNA™ Architect with the advanced and award winning AIR™ Coils
- Installed with two 64-slice CT scanners (GE Discovery CT750 HD and GE LightSpeed VCT)
- Houses CIBC Breast Assessment Center
- JCC is the only CyberKnife® location in southern Ontario

For over 10 years JCC was equipped with an older generation 3.0T MRI scanner. While the previous generation 3.0T scanner was considered efficient, the need for faster scan times and superior image quality drove the installation of SIGNA™ Architect 3.0T with AIR™ Multi-purpose Coils leading to faster workflow and enhanced efficiency.

Prior to the installation of SIGNA™ Architect, the team faced a few challenges with brachial plexus imaging; head and neck; respiratory

triggering, fat saturation and diffusion sequences. Diffusion-weighted images (DWI) especially for prostate imaging were among the key motivators for the facility to install SIGNA™ Architect. Furthermore, the conventional rigid form of coils can be a barrier for positioning the patients correctly.

AIR™ Coils have improved the patient comfort significantly. With abdominal imaging, patients seem to like AIR™ Coils because they are not at all heavy as compared to the previous rigid coil. So certainly, it is more comfortable for the patient.

Judith Baranowski
MRI Senior Technologist Hamilton Health Sciences -
Juravinski Hospital and Cancer Centre

Delivering better patient comfort



“ One of the main drivers for us was to have an improved scan time. The fact that we could improve scan time along with high image quality of a second-generation MRI scanner, were the key drivers that led to the installation of SIGNA™ Architect 3.0T. ”

Dr. Scott Tsai

Radiologist, Hamilton Health Sciences -
Juravinski Hospital and Cancer Centre

Improved image quality and reduction in rescans

The AIR™ Coils were said to comfortably fit the patient and improve diagnostic quality of the images acquired. This has further reduced the rescans and consequently the patient table time has lowered significantly. Among all the procedure types, prostate imaging in large patients has gained significantly from the use of AIR™ Coils. With the fixed rigid coils, the distance between actual prostate and coil was high, thereby impacting the quality of images negatively.

Light weight and comfortable

As a large regional center, the facility receives patients across all stages of cancer. The AIR™ Coils were observed to be very useful for patients with metastatic cancer experiencing high intensity pain. Along with the short scan time, the weight of the AIR™ Coil was found to be more tolerable for patients compared to the rigid coils. Since the AIR™ Coils are light weight and flexible, they contour the patient's body habitus resulting in improved image quality and SNR.

Improved patient comfort during spine imaging

Ensuring patient comfort while imaging the spine for cord compression has been one of the biggest challenges for MR technologists. Most patients are unable to lie flat causing distortion in the image quality. With the SIGNA™ Architect comfort tilt system, the technologists are now able to position the patient consistently, thus ensuring quicker and more comfortable scans.

Reduction in patient positioning, pre-scan and ultimately patient table time

With AIR Touch™, the technologist can automatically select the coil element and the combination that is individualised for each patient at a single touch. Consequently, the patient positioning time has been reduced.

Reduction in scan time

Average pre-scan* time with the new SIGNA™ Architect has reduced. On average, the scan acquisition time of various procedures at the hospital has shortened by approximately 5 minutes². For example, a typical head scan with gadolinium that would have taken ~70 minutes has been reduced to ~31 minutes, including the patient set-up and positioning time. The typical head scan constitutes about 39% of the procedural mix per month, thereby assisting the facility to drive significant operational efficiency.





-  Reduction in scan time enabling shorter table time for the patients
-  Patient-friendly design of the coil that improves positioning flexibility and system utility
-  Light-weight coils that reduce discomfort for patients
-  Snug fit that improves the SNR and image quality

Figure 1: Impact of SIGNA™ Architect with the AIR™ family of technologies – JCC ¹

“ When the cancer is metastasized, the patient is in a lot of pain. They cannot stay in the scanner for long. But more than that, the rigid coils are quite heavy for them to tolerate. Especially when we are imaging liver metastasis in the abdomen. The AIR™ Coils are noticeably light and are easily tolerated by most patients. ”

Judith Baranowski

MRI Senior Technologist Hamilton Health Sciences -
Juravinski Hospital and Cancer Centre

*During pre-scan, several calibrations are performed to insure optimal performance of the specified protocol. This is generally run as an automated process, but can be performed manually for improved performance

Improved efficiency and workflow

Pre-Installation (May-18 to Sep-18)		Post-Installation (May-19 to Sep-19)	
24	Patients per day	26	Patients per day
750	Scans per month	>800	Scans per month
5	Total body exams during the pre-installation phase	~140	Increase in the number of total body exams
5	Chest Exams during the pre-installation phase	~120	Increase in the number of chest exams
		~37%	Increase in MR of Breasts

Figure 2: Impact of SIGNA™ Architect with the AIR™ family of technologies – JCC ¹

“The most important benefit is that we can reduce the scan time without having to compromise on the image quality. SIGNA™ Architect has so many advanced sequences such as FLEX, that will help reduce the scan time, yet improve image quality.”

Dr. Scott Tsai,
Radiologist, Hamilton Health Sciences -
Juravinski Hospital and Cancer Centre

The scan time for MRCP has been reduced by ~11%, saving the facility over 4 minutes per scan². This has resulted in increased throughput and better patient comfort. On a daily basis, the center, saves about an hour from the schedule that can accommodate more than two additional patients per day².

Reduction in patient positioning time:

AIR™ Coils have been extremely helpful in reducing the patient positioning time. Since the AIR™ Coils are light and flexible, patient positioning for accurate registration of region of interest has been effortless. Moreover, automated iso-centering and optimal coil element selection have been driving efficiency for the department.

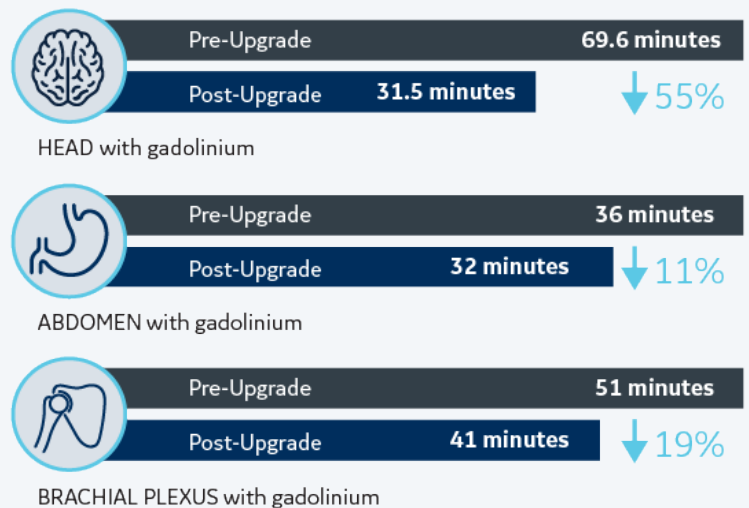


Figure 3: Reduction in scan acquisition time across routine procedures¹

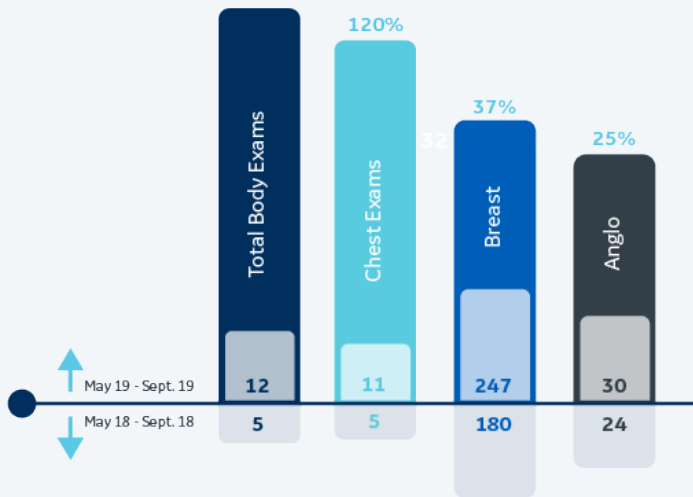


Figure 4: Comparison of procedural volume for advanced cases with previous year¹

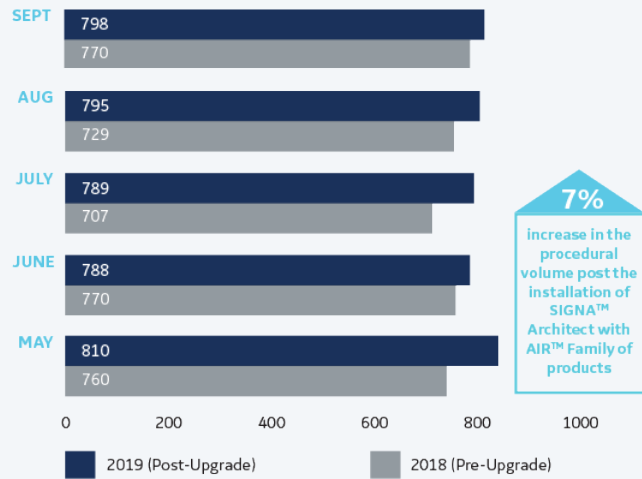


Figure 5: Month on month comparison of procedural volume of MRI scans¹

Especially for extremity imaging, I find AIR™ Coils very useful. While imaging regions such as arms, humerus, shoulders which are technically difficult areas to apply a coil and receive a robust signal, AIR™ Coils have been very beneficial. They are light and easy to carry. We can use them ergonomically without injuring ourselves.

Judith Baranowski
MRI Senior Technologist Hamilton Health Sciences -
Juravinski Hospital and Cancer Centre

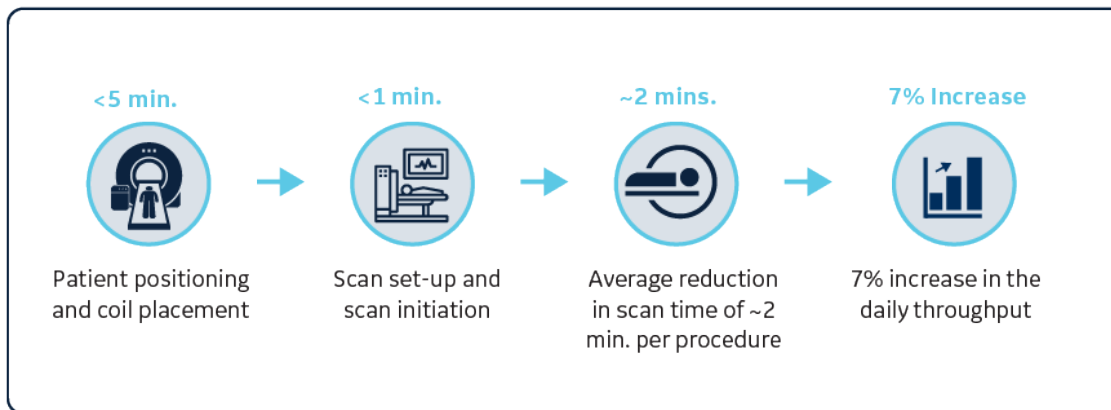


Figure 6: Month on month comparison of procedural volume of MRI scans¹

Improved image quality and diagnostic confidence

I feel that our brain imaging is just superb. We perform MP Rage for post-contrast range and have been able to consistently detect milli-metric sized metastases, which is immensely helpful for our radiation oncologist. We also perform hepato-biliary phase imaging for detecting tiny liver metastases while letting the patients breathe naturally - another area that has been working out well for us.

Dr. Scott Tsai
Radiologist, Hamilton Health Sciences -
Juravinski Hospital and Cancer Centre

Improved image quality in head and brain perfusion imaging

With the AIR™ 48-Channel Head Coils, the center has been able to capture and read slices as thin as 2.5 mm. This has further improved the diagnostic confidence in areas such as neuro imaging and brain imaging. The facility leverages sequences such as post-contrast MP-RAGE, that helps to reduce ghosting artifacts while imaging the skull base, and MUSE that has assisted in capturing DWI and DTI sequences in larger matrix size while reducing susceptibility artifacts and distortion around air-tissue interfaces. This has facilitated better visualization of important anatomy in the region of interest.

Our perfusion imaging is very good. We apply an additional sequence that just takes about a minute. But the increase in the number of sequences for perfusion study exam hasn't required us to increase our amount of time allotted for the exam. We're doing more in the same amount of time, and it is greatly appreciated by our neuroradiology team. It is very easy for us to reconstruct the cerebral blood volume maps. It takes only seconds.

Judith Baranowskii
MRI Senior Technologist Hamilton Health Sciences -
Juravinski Hospital and Cancer Centre

Reduction in motion artifacts in abdominal and whole-body imaging

With sequences such as LAVA Flex, the ghosting or motion artifacts especially in liver imaging have reduced significantly. Additionally, with the help of Auto Navigator, the center has been able to reduce motion and respiratory artifacts while performing liver and abdominal imaging. Consequently, evaluation of liver metastases has improved remarkably even in patients with erratic breathing patterns.

I feel that we are much more confident while detecting liver metastases. This is overly critical for pre-operative planning and for patients undergoing liver resection. The prostate imaging has also improved significantly, as result the number of referrals from urologist across the region has increased.

Dr. Scott Tsai
Radiologist, Hamilton Health Sciences -
Juravinski Hospital and Cancer Centre

We use respiratory triggering or navigator in abdominal imaging. It has been very useful in patients who can't follow breath hold and also with patients who have erratic breathing pattern.

Dr. Scott Tsai
Radiologist, Hamilton Health Sciences -
Juravinski Hospital and Cancer Centre

While conducting body imaging and MRCP, JCC has benefitted from sequences such as 3D LAVA, 3D T2 and DWI. As a result, visualization of the peripheral ductal anatomy of the liver has improved consistently. In addition, fat saturation sequences have been helpful while delivering reliable detection of small pancreatic cyst lesions and associated connections with the main pancreatic duct. Along with clear and sharp images, improved spatial resolution was another key advantage observed.

I really like the respiratory triggered MRCP sequence. I think the axial T2, single shot fast spin echo sequence is very good at generating quality images with high diagnostic value. The multiphase dynamic or multiphase sequences with tracker are quite good. It provides a very easy method to track the bolus.

Judith Baranowskii
MRI Senior Technologist Hamilton Health Sciences -
Juravinski Hospital and Cancer Centre



Improved image quality for all MSK scans especially knee joints and shoulder



Enhanced visualization of peripheral ductal anatomy of liver



Detection of small pancreatic cyst lesions and small connections from those cysts



Ability to capture thin slices that allows detection of sub-millimetric metastases

Figure 7: Impact of SIGNA™ Architect and AIR™ Family of technologies on diagnostic confidence²

High SNR in prostate and extremities imaging

Robust signal and better contouring of the AIR™ Coil with the patient body have further improved the SNR significantly. Technically challenging regions such as shoulder, humerus and ankle are now being scanned effectively with higher precision.

Implementing advanced sequences

The center is expected to further enhance throughput by leveraging more advanced sequences such as BREASE and DISCO. In addition, usage of quantitative analysis applications such as GenIQ and OncoQuant in the future is expected to enhance clinical outcomes for patients.

References:

1. Data procured from the PACS system of Juravinski Cancer Center
2. Based on qualitative discussions conducted with the various stakeholders at JCC on 12th February 2021.

Abbreviation key:

- DWI: Diffusion-weighted imaging
- DTI: Diffusion tensor imaging
- LAVA Flex: A dynamic 3D FSPGR T1-weighted technique that generates 4 contrasts in one rapid acquisition. LAVA Flex can be acquired as a free breathing dynamic scan with Navigator or as a patient breath-hold.
- MRCP: MR cholangiopancreatography
- MUSE: Multi-shot diffusion – Multi-plexed Sensitivity Encoding technique

© 2022 General Electric Company – All rights reserved.

The outcomes are site specific, indicative, and not prescriptive. They could vary depending on site, adoption rate, and circumstances. This case study is based on the experience of our customer. It is not a guarantee of specifications.

GE Healthcare reserves the right to make changes in specifications and features shown herein, or discontinue the product described at any time without notice or obligation. Contact your GE Healthcare representative for the most current information. GE, the GE monogram and AIR™ are trademarks of General Electric company. GE Healthcare is a division of General Electric company. JB19185XX



The radiologists have been particularly pleased with the MSK imaging. The amount of signal and as a result the finer details can be captured in extremity imaging. Areas such as arms, shoulders and elbow that are typically challenging to position and achieve good SNR.



Judith Baranowskii

MRI Senior Technologist Hamilton Health Sciences -
Juravinski Hospital and Cancer Centre

Due to the advanced DWI sequence coupled with the high SNR delivered by AIR™ Coils, the image quality for prostate imaging has improved significantly. Furthermore, generation of the ADC and eADC maps in DWI have become efficient and easy. The FLEX sequence continues to be leveraged frequently because of its fast scan acquisition time and enhanced fat saturation that improves the conspicuity of even small anomalies.



Now that we have such a robust system, with high magnet homogeneity, we can make time to learn and deploy advanced sequences that helps in improving diagnostic confidence. In the past, it has been challenging to use additional sequences because of increased scan time. Being a regional cancer center that is perpetually busy, we anticipate that the system with AIR™ Coils will improve productivity and drive research and clinical excellence.



Dr. Scott Tsai

Radiologist, Hamilton Health Sciences -
Juravinski Hospital and Cancer Centre